International Journal of Maxillofacial Prosthetics (iJMP)

CASE REPORT

Consonant evaluation during fabrication of a removable prosthesis for a cleft lip and palate patient: A clinical report

Ahmed Sameir M. Ali, BDS, MSc, Mariko Hattori, DDS, PhD*, Yuka I. Sumita, DDS, PhD

Department of Maxillofacial Prosthetics, Graduate School, Tokyo Medical and Dental University (TMDU), Tokyo, Japan.

ABSTRACT

Objective consonant evaluation using palatograph tracing and digital acoustic assessment methods are valuable tools for speech assessment that can be used to track speech improvement in patients wearing a removable prosthesis. In this case report, we employed the psychoacoustic parameter – sharpness - to compare the quality of consonants in a cleft palate patient while wearing the old prosthesis, the new prosthesis, and the new prosthesis following palatogram guided modification. The result suggests that sharpness can be successfully analyzed as a criterion to monitor consonants quality during prosthesis fabrication for cleft palate patients. *(Int J Maxillofac Prosthetics 2022;5:22-24)*

Keywords

Palatograph, psychoacoustics, sharpness, cleft lip and palate.

AUDIOABSTRACT

ARTICLE INFO

Corresponding Author:

Dr. Mariko Hattori

Department of Maxillofacial Prosthetics, Graduate School, Tokyo Medical and Dental University (TMDU), 1-5-45, Yushima, Bunkyo-ku Tokyo 113-8549, Japan.

Phone :+81-3-5803-5556

Email: sasamfp@tmd.ac.jp

Received: 31 March 2022
Received in revised form: 07 June 2022
Accepted: 13 June 2022

INTRODUCTION

Cleft lip and palate are common orofacial congenital defect that occurs in isolation or combined with other congenital defects or syndromes. The defect's degree of severity is directly related to the severity of the aesthetics disfigurement and functional defect.[1] Patients with cleft palate frequently have speech difficulties, which are typically exhibited as hypernasality and impaired speech intelligibility.[2-4] Surgical intervention may improve speech production, however, many patients still have speech problems after surgery,[1] mainly due to postoperative complications such as velopharyngeal insufficiency.[1,3,4] Therefore, some studies recommended using a prosthetic obturator to avoid these complications, especially in patients with a large palatal cleft.[1] Furthermore, besides closing the oro-nasal communication and restoring the lost teeth, the palatal surface of the prosthetic obturator can be modified using palatograph technique to improve articulation during speech therapy.[1]

Speech improvement is one of the most crucial aims in cleft palate rehabilitation, and a variety of subjective and objective evaluation tools have been used to evaluate speech in such patients. Subjective methods such as the speech intelligibility test is commonly used, however, it is not accurate as it is perceptually determined and depends on the therapist's skills and judgment.[5] On the contrary, digital acoustic evaluation methods are easy to process and reproducible allowing long-term follow-up.[4-6] In this case report we used the psychoacoustic parameter; "Sharpness" to track consonants articulation characteristics through the old prosthesis, the new prosthesis, and the new prosthesis after palatogram modification in cleft palate patient.

CASE REPORT

A 51-year-old lady presented to the department of Maxillofacial Prosthodontics, Tokyo Medical and Dental University complaining of mobility of her upper prosthesis. The patient had a history of right-side cleft lip and palate and underwent four plastic surgeries. Past dental history includes orthodontic treatment, restorations, and removable partial dentures. Clinical examination (Fig. 1A) revealed a repaired cleft palate at the right maxilla and some of the maxillary front teeth were missing. There were remaining roots, prepared abutments, and OP anchors on the maxillary central incisors. Periodontal

Articles published in Int J Maxillofac Prosthetics are licensed under a Creative Commons Attribution-NonCommercial 4.0 International License.

tissue and remaining teeth were in preferable condition. The denture has a history of fracture and repair (Fig. 1B).

Fabrication of an acrylic-based removable overdenture was planned to restore the masticatory function, phonation, and aesthetics. The remaining teeth and the OP attachments were used to gain additional support and retention for the denture. The prosthesis was fabricated conventionally and then adjusted using palatogram speech evaluation technique.

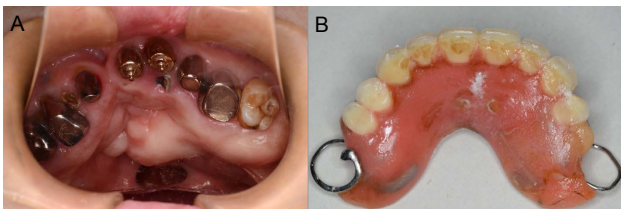

Fig 1. Intraoral view A, Old denture B.

We used conventional palatogram technique (alginate powder) to evaluate the tongue contact while uttering the following syllables: **/aka/**, **/asa/**, and **/ata/** (Fig. 2), and the prosthesis was modified accordingly by reduction or adding self-cure acrylic resin. For psychoacoustic evaluation, the patient was instructed to utter; **/aka/**, **/asa/**, **/ata/**, **/apa/**, and **/atʃi/** three times while wearing the old denture, and the sound was recorded on a computer using a microphone (Fig. 3). The procedure was repeated for the new denture before and after palatogram adjustment. The highest sharpness value of each consonant was analyzed using a psychoacoustic system and the mean of the three times measurement was calculated (Fig. 4).

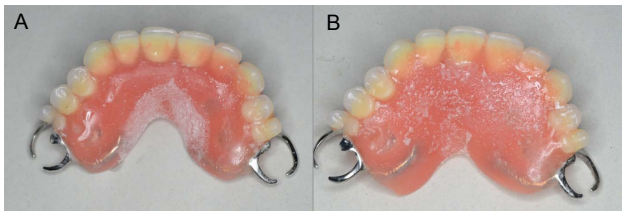

Fig 2. The new denture during palatogram recording, A **/s/** and B **/t/**.

Figure 2 shows the result of the palatogram evaluation for **/t/** and **/s/**. When **/t/** was pronounced there was a rather wide wet area spreading to the palate indicating enough contact of the tongue to the palate (Fig. 2B). When **/s/** was pronounced, the tongue contact area was too large with less airway in the middle indicating that the base of the prosthesis was thick making less airway for making fricative sound (Fig. 2A). The sharpness of **/s/** was lower with the old prosthesis and became higher with the new prosthesis. **/k/** sharpness is considerably elevated after palatogram adjustment. The sharpness of the labial **/p/**, alveolar **/t/**, and post-alveolar **/atʃi/** showed minimal changes between the three conditions (Fig. 4). The patient was satisfied with the adjusted prosthesis and kept visiting for the check twice a year without showing any problems for five years up to now.

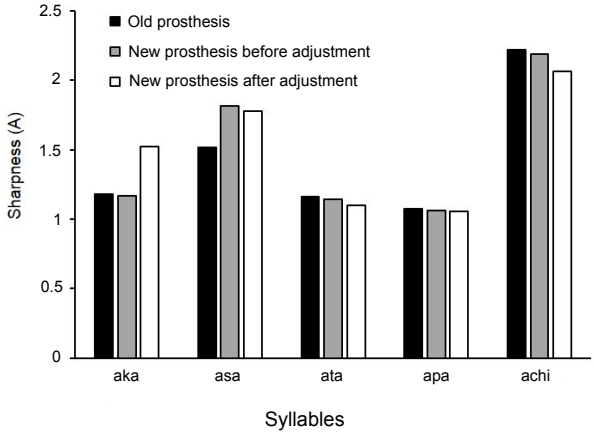

Fig 4. Sharpness of consonant with old denture, new denture and adjusted new denture.

DISCUSSION

Because it allows the prosthodontists to track the progress of the patient's speech, objective digital acoustic assessment is a useful tool for maxillofacial prosthetic rehabilitation.[4] Prosthodontists use this technique to assess patients with speech impairment who require prosthodontic treatment.[5-8] Palatogram is conventionally used to visualize the tongue palate contact during articulation of specific consonant and, determine the parts of the denture that needs adjustment.

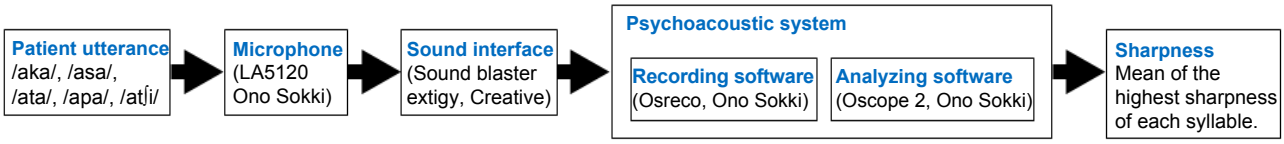

Fig 3. Psychoacoustic evaluation process.

Psychoacoustics correlate the physical characteristics of acoustics to subjective human perception.[6,9] Chowdhury, et al and Hattori et al discovered that of the three psychoacoustic parameters of **Loudness**, **Roughness**, and **Sharpness** that were used to evaluate a speech in maxillectomy patients, Sharpness had the lowest coefficient of variance and was used in their study for comparison.[6,9] Accordingly, we adopted sharpness to be used in this case. Sharpness describes the quality of a sound to sound sharp - as if it were cutting through something - and it is closely linked to how pleasant we find the sound to be. Sharpness is dominated by energy and frequency and, it's a question of the spectral envelop of a sound;[10] if there is strong high-frequency energy in a sound then it will be sharper than if there is no strong high-frequency energy.

The sharpness frequency of **/s/** was increased when the new prosthesis was inserted indicating the articulation improvement compared to the old prosthesis. In their study, Chowdhury et al, demonstrated that **/s/** sharpness increased significantly for maxillectomy patients after using an obturator prosthesis.[6] The **/p/** sharpness showed no changes, this could be attributed as the place of articulation is not involving the prosthesis (labial consonant). For **/t/** and **/tʃ/** we suggest that the articulation patterns remain the same for the three dentures – even after thinning the new denture base - as the sharpness showed no significant differences (Fig. 2B). Although the prosthesiswasn't covering the articulation place for **/k/**, its sharpness increased after adjustment. The cause is thought to be the comfort of wearing the altered prosthesis, which made it more plosive; however, more evidence from other cases is needed to support this theory (Fig. 4).

CONCLUSION

Objective speech analysis utilizing the psychoacoustic parameter sharpness was useful in evaluating and tracking treatment progress and outcomes for cleft lip and palate patients who require a removable denture. More research is needed to compare this variable in a large group of cleft lip and palate patients wearing a prosthesis.

REFERENCES

1. Lopes JF, Pinto JH, de Almeida AL, Lopes MM, da Silva Dalben G. Cleft palate obturation with Brånemark protocol implant-supported fixed denture and removable obturator. Cleft Palate Craniofac J. 2010;47:211-215.
2. Lou Q, Wang X, Jiang L, Wang G, Chen Y, Liu Q. Subjective and objective evaluation of speech in adult patients with unrepaired cleft palate. J Craniofac Surg. 2022. doi: 10.1097/SCS.0000000000008567.
3. Pinto JH, da Silva Dalben G, Pegoraro-Krook MI. Speech intelligibility of patients with cleft lip and palate after placement of speech prosthesis. Cleft Palate Craniofac J. 2007;44:635-641.
4. Villafuerte-Gonzalez R, Valadez-Jimenez VM, Hernandez-Lopez X, Ysunza PA. Acoustic analysis of voice in children with cleft palate and velopharyngeal insufficiency. Int J Pediatr Otorhinolaryngol. 2015;79:1073-1076.
5. Sumita YI, Hattori M, Murase M, Elbashti ME, Taniguchi H. Digitised evaluation of speech intelligibility using vowels in maxillectomy patients. J Oral Rehabil. 2018;45:216-221.
6. Chowdhury NU, Otomaru T, Murase M, Inohara K, Hattori M, Sumita YI, et al, A new simple evaluation method of the monosyllable /sa/ using a psychoacoustic system in maxillectomy patients. J Prosthodont Res. 2011;55:7-11.
7. Elbashti ME, Sumita YI, Hattori M, Aswehlee AM, Taniguchi H. Digitized Speech Characteristics in Patients with Maxillectomy Defects. J Prosthodont. 2019;28:649-655.
8. Hattori M, Sumita YI, Taniguchi H. Measurement of voice onset time in maxillectomy patients. Scientific World Journal. 2014;925707.
9. Hattori M, Sumita YI, Taniguchi H, Psychoacoustic evaluation of the human voice: gender and age differences in the production of 14 consonants. International Journal of Oral Research, 2014;5:e2.
10. Zwicker, E. and H. Fastl, Psychoacoustics: Facts and models. Vol. 22. 2013: Springer Science & Business Media.